



Primary malignant teratoma of the mediastinum with poor outcome: A case report

Primarni maligni teratom medijastinuma sa lošim ishodom

Danica Sazdanić-Velikić*, Dušan Škrbić†, Djordje Považan†, Mirna Djurić†,
Dejan Vučković‡, Nevena Sečen*

University of Novi Sad, Faculty of Medicine, Institute for Pulmonary Diseases of
Vojvodina, *Clinic for Thoracic Oncology, †Clinic for General Pneumology, ‡Center for
Pathology, Sremska Kamenica, Serbia

Abstract

Introduction. About 5%–10% of mediastinal tumors in adults are teratomas and about 85% of them are benign. **Case report.** We report a case of extragonadal malignant teratoma in a 39-year old man. The computed tomography (CT) scan of the chest revealed the soft-tissue density mass in the middle lobe of the lung. The posterolateral thoracotomy was performed and a mediastinal tumor of 25 cm was completely resected. Histopathological findings confirmed malignant teratoma. One month after the resection the positron emission tomography-computed tomography (PET/CT) scan of the whole body was performed and showed progression of the disease. Patient developed signs of the superior vena cava obstruction and received radiotherapy of the mediastinum and the metastatic lesion of the lumbar vertebra. After radiotherapy, the patient developed paraplegia and urinary incontinence and received the best supportive treatment. **Conclusion.** Primary extragonadal germ cell tumors have poor prognosis due to their relative chemoresistance and frequent findings of advanced disease after establishing the diagnosis.

Key words:

teratoma; mediastinal neoplasms; diagnostic techniques and procedures; thoracic surgery; neoplasm metastasis; radiotherapy; palliative care.

Apstrakt

Uvod. Oko 5% –10% medijastinalnih tumora kod odraslih su teratomi, od kojih su prosečno 85% benigni. **Prikaz slučaja.** Prikazujemo slučaj ekstragonadalnog malignog teratoma kod bolesnika starog 39 godina. Kompjuterizovanom tomografijom (KT) grudnog koša uočena je mekotkivna promena u srednjem režnju desnog plućnog krila. Posterolateralnom torakotomijom viđen je medijastinalni tumor veličine 25 cm koji je u potpunosti odstranjen. Patohistološki nalaz resektata potvrdio je maligni teratom. Jedan mesec nakon resekcije pluća urađena je pozitron emisiona tomografija – kompjuterizovana tomografija (PET-CT) celog tela koja je ukazala na progresiju bolesti. Kod bolesnika je došlo do razvoja znakova kompresije na gornju šuplju venu, zbog čega je sprovedena radioterapija medijastinuma i palijativna radioterapija metastatske promene na lumbalnom pršljenu. Nakon radioterapije bolesnik postaje inkontinentan i paraplegičan, te je nadalje sprovedena najbolja potporna terapija. **Zaključak.** Primarni ekstragonadalni tumori imaju lošu prognozu usled njihove relativne hemorezistencije i čestog nalaza uznapredovale bolesti u momentu postavljanja dijagnoze.

Ključne reči:

teratom; medijastinum, neoplazme; dijagnostičke tehnike i procedure; hirurgija, grudna; neoplazme, metastaze; radioterapija; lečenje, palijativno.

Introduction

Teratoma is a special mixed tumor type that contains mature or immature cells or tissues derived from more than one germ cell layer, or sometimes of all three (ectoderm, endoderm, mesoderm)^{1,2}. Germ cells are those of the gonads

and there are several theories explaining their presence in other locations. According to the theory that the origin of this tumor is anatomically related to the thymus, it is supposed that in an early embryo the primordial teratomatous focus is originally located in the thymus and may lie in such a position in the mediastinum that it is caught up and carried by the

respiratory outgrowth from the foregut^{3,4}. Germ cell tumors are classified as extragonadal tumors when there is no presence of primary tumors of testes or ovary. The most common localization of extragonadal tumors in adults are pineal gland, mediastinum and retroperitoneum⁵⁻⁷. Teratoma is a common tumor of the anterior mediastinum and malignant teratoma seldom metastasizes to the lung. The most frequently involved extrathoracic metastatic site is the skeletal system^{8,9}. About 5%–10% of mediastinal tumors in adults are teratomas and about 85% of them are benign^{1,9-12}. The world wide annual incidence of teratomas is about 1 in 4000 live births^{12,13}. Risk factors for malignant extragonadal germ cell tumors include: a male sex, the age of 20 or older, Klinefelter syndrome^{5,14}.

Case report

We report a case of a malignant teratoma in a 39-year-old man who presented with cough, high body temperature and shortness of breath. The chest radiography (X-ray) finding showed a massive, homogenous infiltration in the lower 2/3 of the left lung (Figure 1).

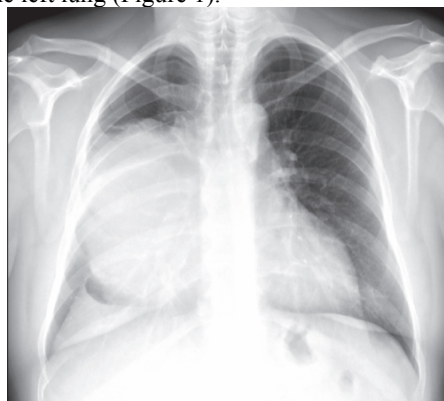


Fig. 1 – Chest X-ray finding at the admission: A massive, homogenous infiltration in the lower 2/3 of the right lung.

The computed tomography (CT) scan of the chest revealed a soft tissue density mass in the middle lung lobe sized 15×13×13 cm, with a compression of the right hilar region, left and right atria and superior vena (Figure 2).

Bronchoscopy with endoscopic biopsy and transthoracic needle biopsy were performed, but obtained samples were insufficient to diagnose radiologically found lesions. Posterolateral thoracotomy was performed and a mediastinal tumor of 25 cm in size was seen on videoassisted thoracoscopy and it was completely resected. At the gross examination, the resected mass measured 17×14×13 cm and weighed 1,300 g, it was circumscribed, oval in shape, with a smooth surface. At cross section, it is mostly gray whitish, rather firm and with some yellowish softend areas. Diffusely, small to medium cysts were present. On histology, the tumor consisted of various tissue types: fibrous, mature cartilage, smooth muscle bundles, nervous tissue with ganglionic cells, many cysts lined with columnar epithelial cells and malignant tumorous tissue. Some areas were necrotic and others with old and fresh haemorrhage (Figure 3).

The malignant tissue consisted of atypical, pleomorphic epithelial cells rather large with hyperchromatic nuclei and visible pathologic mitosis. The cells were arranged into diffuse sheets and some tubular or glandlike patterns. The zones of coagulative necrosis in the tumor nests, with some cellular debris were present. The immunohistochemical analysis showed the alpha-fetoprotein (AFP) and AE1/AE3 positivity in all tumor cells and CD30 focal positivity in about 10% of the tumor cells. The positive vimentin staining was in mesenchymal components and S100 in the nervous tissue. The negative staining was for placental-like alkaline phosphatase (PLAP) and CD117 (Figure 4). Based on the morphology and immunohistochemical characteristics of the tumor, the diagnosis of mediastinal teratoma with a component of a malignant mixed germ cell tumor has been established, with a predominating embryonal carcinoma as the main part.

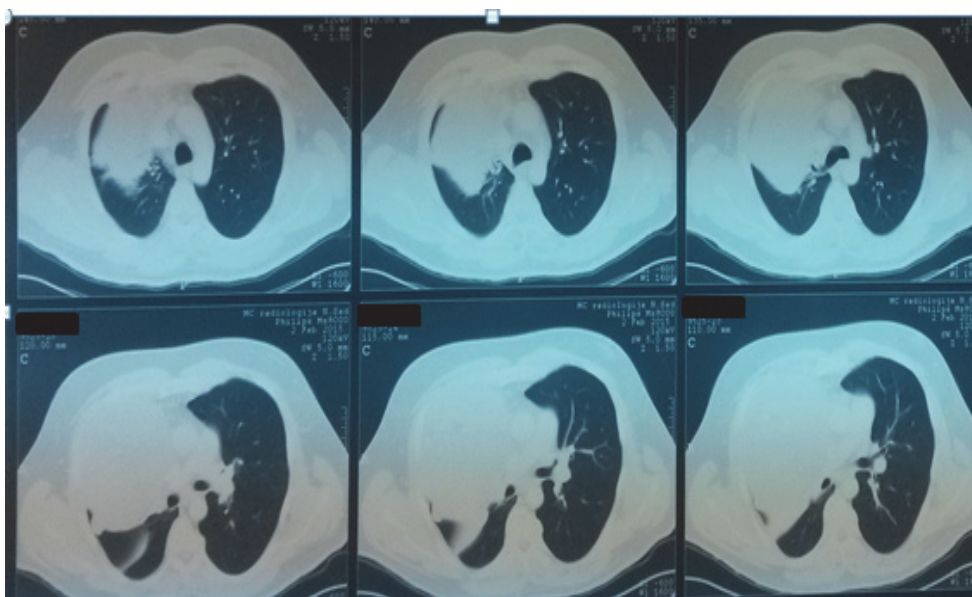


Fig. 2 – Chest computed tomography scan at the admission.

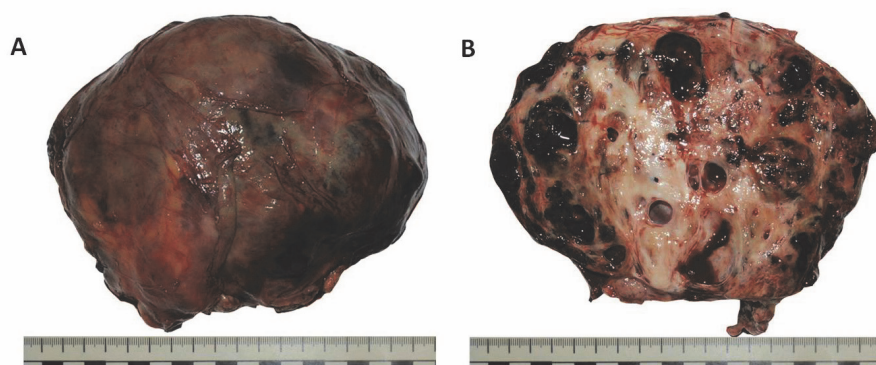


Fig. 3 – A) Gross appearance of the resected mass; B) Cross section of the tumor.

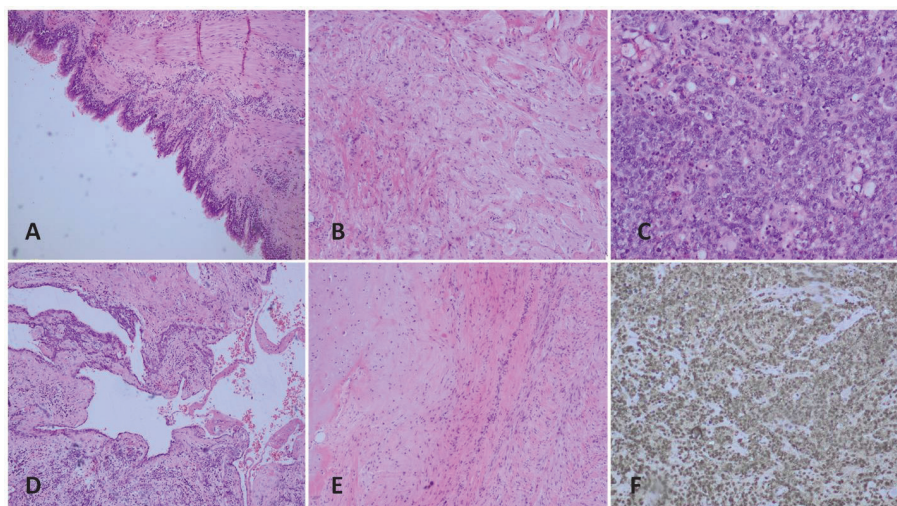
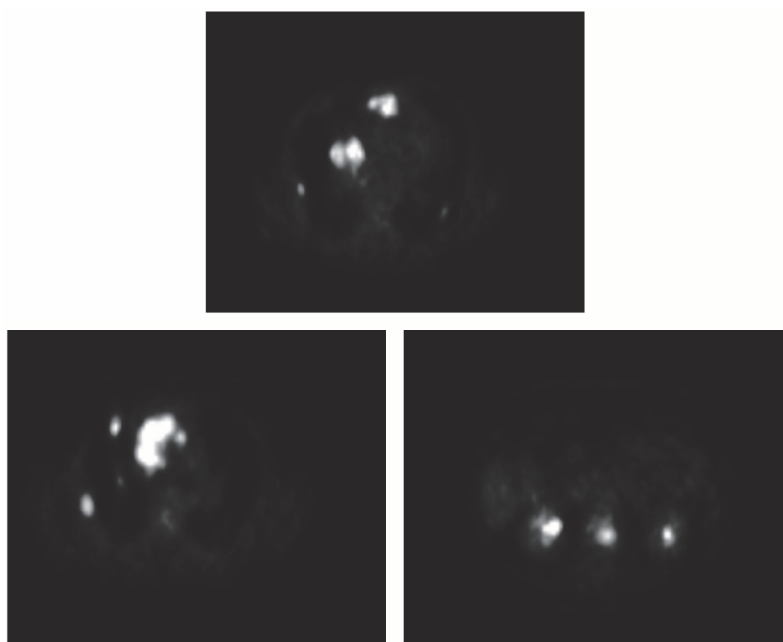


Fig. 4 – Respiratory epithelium [hematoxylin eosin (H&E), $\times 100$]; B) Nervous tissue (H&E, $\times 40$); C) Embryonal carcinoma (H&E, $\times 100$); D) A cyst lined with cuboidal cells (H&E, $\times 40$); E) Cartilaginous, fibrous changes in nervous tissue (H&E, $\times 40$); F) Alpha-fetoprotein (AFP) positive carcinoma cells (AFP, $\times 100$).



**Fig. 5 – PET/CT scan of the whole body.
PET/CT – positron emission tomography/computed tomography.**

One month after the resection, the patient underwent the positron emission tomography-computed tomography (PET/CT) scan of the whole body which showed multiple focuses of the fluorodeoxyglucose (FDG) activity in the anterior mediastinum, multiple subpleural focuses in the right lung, micronodular lesions in both lungs and focuses of FDG activity in the 1st to 2nd lumbar vertebral body (Figure 5).

The serum AFP level was extremely high – 14,260 ng/mL (the normal value ranges from 0.6–6.6 ng/mL), and the serum beta human chorionic gonadotropin (β -HCG) value was within the normal range. Ultrasonography of the testis was normal. Having developed the signs of the superior vena cava obstruction, the patient received two series of radiotherapy of the mediastinum in the dose of 20 Gy/5 fractions (split-course) and palliative radiotherapy of the lumbar 1st–2nd vertebrae in the dose of 20 Gy/10 fractions. In the course of radiotherapy, the patient developed paraplegia, urinary incontinence and his general condition worsened. After radiotherapy, the patient received the best supportive care.

Discussion

Extragonadal germ cell tumors can be benign (benign teratomas, teratodermoids) or malignant (seminoma or non-seminoma). Nonseminoma tumors are: teratocarcinoma, choriocarcinoma, embryonal carcinoma, endodermal sinus or yolk-sac tumors. Mixed nonseminoma tumors are the most common^{4, 5, 11, 15}. Only 20% of extragonadal germ cell tumor are malignant. Malignant extragonadal teratomas are rare and are usually presented as a mediastinal mass. A rapid growth and invasive behavior are the rule¹⁵. The usual signs and symptoms of malignant extragonadal germ cell tumors due to a local extension of the tumor are: chest pain, breathing problems, cough, fever, headache, change in bowel habits, fatigue, walking problems, vision problems, symptoms due to elevated β -HCG levels (gynecomastia, hyperthyroidism)^{5, 8, 9}. Our patient developed the superior vena cava obstruction signs.

Diagnosis of extragonadal germ cell tumors is based on the: physical examination and history taking, chest X-ray, level of the serum tumor markers (AFP, β -HCG, lactate dehydrogenase – LDH), CT scan of the chest, abdomen or brain, magnetic resonance imaging, PET/CT scan of the whole body, ultrasonography of the testicles, tumor biopsy with pathohistological and immunohistochemical analysis. Blood levels of the tumor markers signify if the tumor is seminoma or nonseminoma. Nonseminomatous germ cell tumors produce high levels of AFP, β -HCG or both, while in seminoma

tumors secretion of β -HCG is low¹⁰. The presence of tumor markers is of great value in the diagnosis and monitoring a patient's response to treatment, as they tend to become negative if the treatment is appropriate⁴. CT scan of the chest is the imaging technique of choice in evaluating the mediastinum; teratomas are often presented as multi-locular cystic tumors, a heterogeneous mass in the anterior mediastinum containing the soft-tissue, fluid, fat or calcium attenuation¹³. Magnetic resonance imaging (MRI) is used in conjunction to CT scanning in the evaluation of the nature, location and extent of the disease¹¹. Varying proportion of mesodermal, ectodermal and endodermal elements are seen on the excised tumor microscopy^{5, 13}.

In our case, the diagnosis was confirmed by thoracotomy obtained biopsy sample. The serum levels of (AFP and LDH) were elevated, while the serum β -HCG level was normal, as well as ultrasonography findings of the testicles.

Surgical excision is the treatment of choice in non-seminomatous tumors and a radical extirpation results in a long recurrence-free-survival^{7, 16}. The postoperative irradiation therapy should be applied if a residual disease or nodal metastases are registered, whereas the preoperative irradiation therapy is indicated if there is evidence of the chest wall involvement³. Recommended chemotherapy protocols include PVB (cisplatin, vinblastin, bleomycin), PEB (cisplatin, etoposide, bleomycin) and JEB (carboplatin, etoposide, bleomycin)⁷.

Mediastinal mature teratomas have an excellent prognosis after complete resection in all age groups, while the prognosis of immature teratoma is still debated due to limited experience¹. Primary extragonadal germ cell tumors have worse prognosis than that for testicular germ cell tumors due to their relative chemoresistance and frequent findings of the disseminated metastases at diagnosis¹⁷.

Conclusion

Primary extragonadal germ cell tumors have poor prognosis due to their relative chemoresistance and frequent findings of advanced disease after establishing the diagnosis. We reported a case of a malignant teratoma of the mediastinum, characterized with a very rapid growth and poor prognoses.

Conflict of interest

We did not receive any financial support for this work and there is no conflict of interest.

REFERENCES

1. *Moreira AL, Chan JK, Looijenga LH, Marx A, Stroebel P, Ulbright TM, et al.* Germ cell tumours of the mediastinum. In: *Travis WD, Brambilla E, Burke AP, Marx A, Nicholson AG, editors.* WHO Classification of Tumours of the Lung, Pleura, Thymus and Heart. 4th ed. Geneva: World Health Organization; 2015. p. 244–66.
2. *Vitorović D, Rosenblum J, Thomas C, Lee J, Biller J.* Primary CNS teratocarcinoma. *Front Neurol* 2012; 3: 14.
3. *Giunchi F, Segura JJ.* Primary malignant teratoma of lung: Report of a case and review of the literature. *Int J Surg Pathol* 2012; 20(5): 523–7.
4. *Mainieri-Hidalgo J, Rees-Alpizar V, Gamboa-Gonzalez I, Maniery-Breedy M.* Mediastinal germ cell tumors. Surgical experience with twenty nine patients. *Acta Méd Costarric* 2013; 55(3):128–131. (Spanish)

5. Extragonadal Germ Cell Tumors Treatment. National Cancer Institute. [cited 2015 Apr 2]. Available from: <http://www.cancer.gov/types/extragonadal-germ-cell/patient/extragonadal-treatment-pdq>
6. Kantoff P. Extragonadal germ cell tumors involving the mediastinum and retroperitoneum. [cited 2015 Sep 10]. Available from: <http://www.uptodate.com/contents/extragonadal-germ-cell-tumors-involving-the-mediastinum-and-retroperitoneum>
7. Roy M, Bandyopadhyay R, Pandit N, Sengupta S. Superior Vena cava Syndrome: A Presenting Feature of Mediastinal Germ Cell Tumor. *Oman Med J* 2010; 25(2): 131–3.
8. Singhal M, Jhavar D. Primary mediastinal giant teratocarcinoma. *Indian J Cancer* 2008; 45(2): 73–4.
9. Hainsworth J. Malignant mediastinal Germ Cell Tumors. 2011. [cited 2011 Feb 12]. Available from: <http://www.health.am/cr/malignant-germ-cell-tumors>
10. Mueller D. Teratomas and Other Germ Cell Tumors of the Mediastinum. 2015. [cited 2015 Nov 2]. Available from: <http://www.emedicine.medscape.com/article/427395>
11. Khan N. Mediastinal Germ Cell Tumor Imaging. 2015. [cited 2015 Nov 2]. Available from: <http://www.emedicine.medscape.com/article/359110>
12. Nuti R, Bodhiredy S, Thirumala S. Mixed germ cell tumor of mediastinum/lung masquerading as hemangioma in fine needle biopsy. *Indian J Pathol Microbiol* 2013; 56(2): 158–60.
13. Kudlinski D, Rubis P, Rudnicka-Sosin L, Leśniak-Sobelga A, Kostkiewicz M, Podolec P. Large mediastinal teratoma causing recurrent pericarditis (RCD code: VI). *J Rare Cardiovasc Dis* 2014; 1(6): 29–32.
14. Weerakkody Y, Danaber L. Mediastinal teratoma. Available from: <http://radiopaedia.org/articles/mediastinal-teratoma>
15. Kundu S, Mandal S, Sngupta A, Dey A. A rare case of primary mediastinal non-seminomatous germ cell carcinoma in a 18 year old boy. *Case Rep* 2006; 23(4): 151–3.
16. Dar RA, Mushtaque M, Wani SH, Malik RA. Giant intrapulmonary teratoma: a rare case. *Case Rep Pulmonol* 2011; 2011: 298653.
17. Buchler T, Dusek P, Brisuda A, Simonova K, Fencl P, Jarkovsky J, et al. Positron Emission Tomography and clinical predictors of survival in primary extragonadal germ cell tumors. *Klin Onkol* 2012; 25(3): 178–83.

Received on March 31, 2016.

Accepted on November 15, 2016.

Online First December, 2016.